

THE ROLE OF ELECTROMYOGRAPHY IN IMPROVING THE EFFECTIVENESS OF PROSTHETICS UNILATERAL END DEFECTS USING IMPLANTS

M. V. Goman¹, I. A. Zaborovets¹, Ars. A. Chagarov¹,
V. M. Avanisyan¹, G. G. Kazarian²

¹Stavropol State Medical University of the Ministry of Health of the Russian Federation, Stavropol, Russian Federation.

²The Peoples Friendship University of Russia (RUDN University); 117198, Russia, Moscow

SUMMARY

This article discusses the role of electromyography in prosthetics of dentition defects, as well as the use of dental implants to increase the biopotentials of masticatory muscles.

KEY WORDS: *electromyography, unilateral end defects, activity of the masticatory muscles.*

CONFLICT OF INTEREST. *The authors declare no conflict of interest.*

Introduction

Rehabilitation of patients with occlusal tooth loss with unilateral terminal defect (second class according to Kennedy) is a difficult task in orthopedic dentistry. Such patients are adapted to chewing on one side for a long time and get to the doctor with advanced pathology due to the prolonged absence of complaints from the dental-maxillary system [1,2,4,5].

When chewing food on one side, due to increased functional load, a pathological symptom complex develops – deformation of the dentition, erosion of the teeth of antagonists, restructuring of the receptor field of the oral cavity, changes in the chewing muscles [3,4].

With a unilateral terminal defect on the side of teeth having antagonists, signals go from periodontal proprioceptors to the sensitive nucleus of the trigeminal nerve, then to the motor nucleus, and then to the masticatory muscles, which contributes to the restructuring of the function of the masticatory muscles. A unilateral type of chewing and forced occlusion is formed [6]. According to Zhulev E. N., 2000, with partial loss of teeth, a decrease in the frequency and amplitude of surface EMG was revealed and a violation of the synchronous activity of the masticatory muscles was indicated [9].

There are several methods of orthopedic treatment of the second class according to Kennedy (unilateral distally unlimited defects of dentition) – removable and non-removable structures.

According to a number of authors, the preferred method of treatment for partial tooth loss is fixed structures supported by implants [7,8]. Fixed structures supported on implants are also the most comfortable for the patient in the absence of contraindications. However, in the available literature there is not a significant amount of data on the effectiveness of this method of treatment for unilateral terminal defect according to the description of electromyography of the masticatory muscles.

The aim of our study was to study the data of surface electromyography of the masticatory muscles before and after the restoration of masticatory function during prosthetics on implants of unilateral terminal defects.

Materials and methods of research

32 patients of both sexes aged 37–53 years were examined to study the dynamics of adaptation to fixed structures based on implants that restore unilateral terminal defects. All patients, from anamnesis, had a unilateral distal-unlimited defect for at least one year. Patients with the absence of 2 to 4 teeth in the lateral section were fitted with 4x10 mm or 4x12mm Conmet implants according to a two-stage method. After the integration of the implants, orthopedic treatment was performed. All patients received metal-ceramic prostheses with screw fixation. The formation of the occlusal surface was performed in an articulator in accordance with generally accepted recommendations [1,3].

Adaptation to dentures was assessed using surface electromyography of the masticatory and temporal muscles before and after fixation of the denture on implants. The study used a portable electromyograph FREELY by De Gotzen (Italy), which automatically processes the data obtained with a special set of programs compatible with Windows and allows you to present the results of EMG in the form of tables and diagrams. EMG control was carried out on the 7-th, 14-th day, 1 time a month for six months. Disposable cutaneous bipolar electrodes with a diameter of 10 mm with an interelectrode distance of 21 mm were used for EMG. One electrode was fixed as a reference on the forehead (Fig. 1).

Conclusions and recommendations

The total electrobiopotential of all muscles – 1151± 263 $\mu V \cdot sec$ was obtained before the start of orthopedic treatment. At the same time, the index of lateral displacement of the

lower jaw (normally up to 10 %) was $-19.9 \pm 5.5\%$, and the index of symmetry of the temporal muscles and masticatory muscles (in the norm of 80–100 %) was $57.2 \pm 6.8\%$ and $-75.68 \pm 5.8\%$, respectively.

After fixation of the denture on implants, the total electrobiopotential of all muscles decreased to $1113 \pm 180 \mu\text{V} \cdot \text{sec}$. While the index of symmetry of the temporal muscles increased to $83.29 \pm 0.93\%$ ($p < 0.05$), which corresponds to the norm, and the masticatory muscles increased to $84.34 \pm 1.16\%$. The index of lateral displacement of the mandible decreased to normal values, and amounted to $10.37 \pm 0.75\%$.

After a month, the total electrobiopotential of all muscles increased to $1468 \pm 202 \mu\text{V} \cdot \text{sec}$, the index of lateral displacement of the mandible approached zero ($0.8 \pm 0.04\%$), and the indices of symmetry of the temporal and masticatory muscles were recorded within the normal range ($87.07 \pm 0.67\%$ ($p < 0.05$) and $86.33 \pm 0.84\%$, respectively). Electromyography performed after 6 months showed an increase in the total electrobiopotential to $1703 \pm 207 \mu\text{V} \cdot \text{sec}$, and the remaining indicators did not statistically significantly differ from the values recorded in previous periods of the study.

A clinical case. Patient T., 47 years old, went to the clinic complaining of an aesthetic defect and difficulty chewing food. There are 2.4, 2.5, 2.6, 2.7 teeth missing on the upper jaw, which were removed for various reasons more than a year and a half ago. To replace the defect of the dentition in the area of the missing 2.4, 2.6, 2.7, Conmet implants were installed using a two-stage $4 \times 12 \text{ mm}$ technique. After 3 months, gum shapers were installed (Fig. 2).

According to the traditional method, a metal-ceramic conditionally removable structure with screw fixation was made (Fig. 3,4).

EMG analysis before applying a bridge-like prosthesis supported by implants on the right side of the maxilla revealed asymmetries in the work of the temporal muscles 50, 26 %, and the masticatory muscles 74, 55 %. The norm for symmetrical operation is 80–100 %

Analysis of the work of the same muscles criss-cross – symmetry of the masticatory on the right and temporal on the left, and vice versa, that is, the index of lateral displacement of the lower jaw was 35, 84 %, while the norm is up to 10 %.

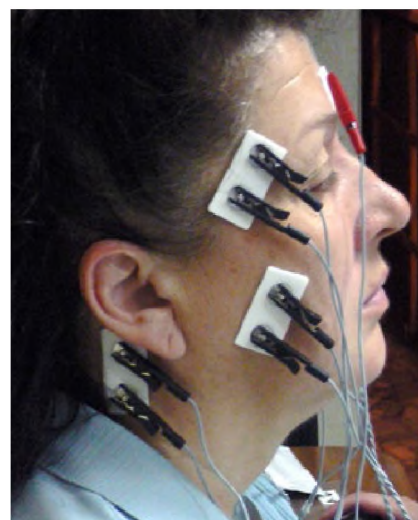

Fig. 1. Cutaneous bipolar electrodes when working with a portable electromyograph FREELY by De Gotzen (Italy)

The total potential of all muscles was $996 \mu\text{V} \cdot \text{sec}$, which is within the normal range (from 500 to $2500 \mu\text{V} \cdot \text{sec}$) (Fig. 5).

After applying the denture, symmetry in the work of the masticatory and temporal muscles was obtained by 84, 51 % and 83, 16 %, respectively, the index of lateral displacement was 10, 64 %. The total potential of all muscles decreased and amounted to $783 \mu\text{V} \cdot \text{sec}$ (Fig. 6).

After 1 month, the total potential of all muscles increased by $1064 \mu\text{V} \cdot \text{sec}$.

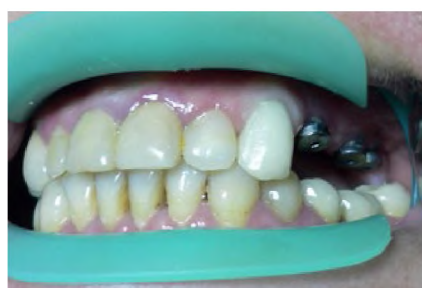

Fig. 2. Gum shapers on implants in the area of 2.4, 2.6, 2.7 teeth

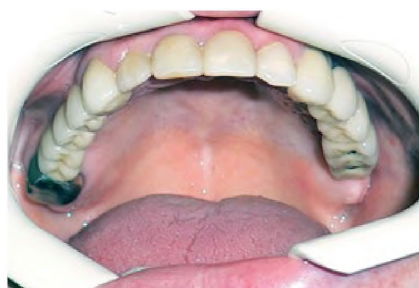

Fig. 3. Metal-ceramic prosthesis with screw fixation on implants in the area of 2.4, 2.6, 2.7 teeth

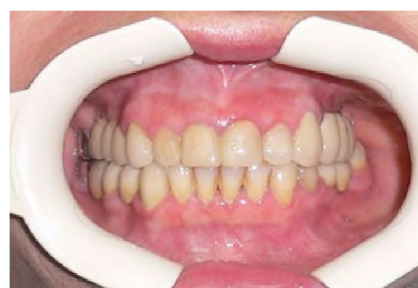

Fig. 4. View of the oral cavity with a dental prosthesis on implants in the area of 2.4, 2.6, 2.7 teeth

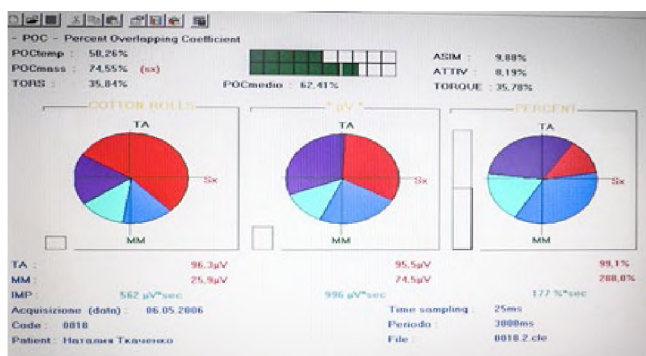


Fig. 5. EMG before fixing the prosthesis

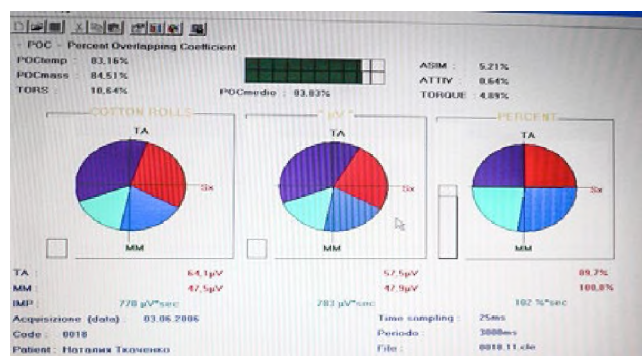

Fig. 6. EMG after applying and fixing the prosthesis

After 6 months, the total potential of all muscles increased and amounted to 1228 $\mu V \cdot sec$. The remaining indicators retained the previously obtained values of the activity of the masticatory and temporal muscles. The symmetry of the muscles remained at the previously obtained level, and the lateral displacement index approached zero.

From all of the above, a preliminary conclusion can be drawn. The restoration of a unilateral distal-unlimited defect of the dentition with dentures on implants is an effective method of prosthetics and actually restores the masticatory function within up to 1 month after the fixation of the prosthesis, which is objectively confirmed by the restoration of symmetrical work of the masticatory muscles and, as a consequence, the formation of a bilateral type of mastication.

References

1. Electromyographic assessment of neuromuscular coordination of masticatory muscles in patients with prosthetics on implants / V. F. Ferrario, G. M. Tartaglia, M. Maglione, M. Simion, Ch. Sforza // *New in dentistry*. 2007. No. 2. P. 46–50.
2. Fernandez-Estevan L, Selva-Otaola E, Montero J, Sola-Ruiz F. Oral health-related quality of life of implant-supported overdentures versus conventional complete prostheses: retrospective study of a cohort of edentulous patients. *Med Oral Patol Oral Cir Bucal*. 2015;20(04): e450–e458.
3. Khvatova V. A. *Clinical gnathology* / V. A. Khvatova – M.: OJSC ed. «Medicine», – 2005. – 296s.
4. Ivanov S. Yu., Muraev A. A., Fomin M. Yu., Dymnikov A. B. The use of dental implants in the complex treatment of patients with mesial occlusion complicated by partial secondary adentia // *J. Stomatology* No. 3, volume 92, 2013, pp. 38–42 //
5. Pellicer-Chover H, Cervera-Ballester J, Peñarrocha-Oltra D, Bagán L, Peñarrocha-Diago MA, Peñarrocha-Diago M. Influence of the prosthetic arm length (palatal position) of zygomatic implants upon patient satisfaction. *Med Oral Patol Oral Cir Bucal*. 2016;21: e380–4.
6. Raikar S, Talukdar P, Kumari S, Panda S K, Oommen V M, Prasad A. Factors affecting the survival rate of dental implants: a retrospective study. *J Int Soc Prev Community Dent*. 2017;7(06):351–355
7. Telescopic and locking fastenings of dentures / I. Yu. Lebedenko, A. B. Peregodov, T. E. Glebova, A. I. Lebedenko // *M.: Young Guard*. – 2004. – 344s.
8. Tsujisaka, A., Haraki, S., Nonoue, S., Mikami, A., Adachi, H., Mizumori, T., ... Kato, T. (2018). The occurrence of respiratory events in young subjects with a frequent rhythmic masticatory muscle activity: A pilot study. *J Prosthodont Res*, 62, 317–323.
9. Zhulev E. N. Partial removable dentures (theory, clinic and laboratory equipment) / E. N. Zhulev – N. Novgorod. – 2000. – 428s.

Received 03.12.2021

Revised 04.12.2021

Accepted 14.12.2021

INFOTMATION ABOUT AUTHORS

Goman Maxim Viktorovich, candidate of Medical Sciences, Associate Professor of the Department of Prosthodontic Dentistry of Stavropol State Medical University of the Ministry of Health of the Russian Federation, Stavropol, Russian Federation, e-mail: maxgoman@mail.ru, +7-962-449-91-82.

Zaborovets Irina Anatolyevna, candidate of Medical Sciences, Assistant of the Department of Prosthodontic Dentistry of Stavropol State Medical University of the Ministry of Health of the Russian Federation, Stavropol, Russian Federation, e-mail: irinazaborovets@mail.ru, +7-962-449-91-84.

Chagarov Arsen Akhmatovich, Postgraduate Student, Department of General Practice and Pediatric Dentistry, Stavropol State Medical University, Ministry of Health of the Russian Federation, Stavropol, Russian Federation, e-mail: Megalwin188@mail.ru, + 7-905-421-33-60.

Avanisyan Vazgen Mikhailovich, the 5-th grade student of the Faculty of Dentistry of the Stavropol State Medical University of the Ministry of Health of the Russian Federation, Stavropol, Russian Federation, e-mail: avanvaz@yandex.ru, +7-928-633-89-95, ORCID: <https://orcid.org/0000-0002-0316-5957>

Kazarian Gerikh Gevorgovich (G.G.), The Peoples Friendship University of Russia (RUDN University); 117198, Russia, Moscow, Miklukho-Maklaya str. 6; Address: 117198, Moscow, Miklukho-Maklaya 10, Medical center; genro96@mail.ru, +79013307370; ORCID 0000-0002-3532-983X