

THE BILATERALLY MISSING MAXILLARY LATERAL INCISORS: AN INTERDISCIPLINARY APPROACH

M.A. Matyuta¹, U.B. Edisherashvili¹, A.A. Dolgalev¹, A.V. Stomatov², N.L. Lezhava³

¹Department of General Practice and Pediatric Dentistry, Stavropol State Medical University, Ministry of Health of the Russian Federation, Stavropol, Russian Federation.

²Department of Maxillofacial Surgery of Penza State University, Penza, Russian Federation.

³Oral and Maxillofacial surgery department, The Peoples' Friendship University of Russia, 6 Miklukho-Maklaya St., Moscow, 117198, Russian Federation

SUMMARY

Nowadays congenitally missing lateral incisors is a common clinical occurrence. Successful dental treatment is always the goal for patients and dental practitioners. In this abstract, the authors introduce an approach using dental implants to solve the problem of congenitally missing lateral incisors. In most cases, a multidisciplinary treatment plan has to be developed and executed. Currently, a single implant supported crown is a predictable method for the treatment of bilateral missing incisors.

KEY WORDS: genesis of maxilla, lateral incisors implant.

CONFLICT OF INTEREST. The authors declare no conflict of interest.

Funding. Funding for the study was carried out from the personal funds of the authors.

Introduction

Adentia (pathology of dental eruption) - a pathology of dental system incidences which, according to various authors, ranges from 1.5 to 8%. In terms of spreading, adentia of the lateral maxillary incisors, caused by a lack of the tooth buds, has been ranked firstly between the absent second premolars and third molars. The reasons for the lack of permanent buds of these teeth are polyethiological factors such as genetic predisposition, or dental system developmental disorders during the development of the fetus. There is also a point of view about the evolutionary reduction in the number of teeth in humans.

We performed a retrospective analysis of the treatment and rehabilitation of patients with missing lateral maxillary incisors. We analyzed 62 sources, which have been published from 2004 to 2020. This allowed us to compile information on the disease.

In recent years, this pathology has become a quite frequent reason for patients looking for treatment, especially young women. The treatment of adentia of the lateral maxillary incisors, in connection with increased aesthetic demands by the patient, is a rather complex problem today and has its principal features. There are many factors that need to be considered in the treatment of this disease, such as the patient's age, the location of the defect, the limited space between the teeth, the lack of tissue in the alveolar ridge, an uneven contour ridge, often a thin gingival biotype or occlusional and periodontal problems.

The following methods of rehabilitation for patients with these pathologies (prosthodontic, orthodontic,) and the principle of a multidisciplinary approach to the treatment are described in the literature.

The usual types of restorations used in orthopedic treatment are as follows: the removable dentures, fixed prostheses in the form of cantilever structures and non-removable adhesive design with a metal or fiberglass base.

The removable dentures are not esthetic or comfortable. Fixed bridges require the preparation of two or four neighbouring teeth, normally healthy ones. Adhesive dentures are short-lived.

For orthodontic treatment, there are two main approaches: the orthodontic movement of canines in to the location of missing incisors, or canines moved distally to create space for the same orthopedic restoration or implant prosthetics, which follow it. A method to close the space between medial incisors and canines requires remodeling canines and premolars.

To date, the preferred method for the rehabilitation of these patients is the installation of implants in this manner.

This treatment is based on a multidisciplinary approach for rehabilitation and is practiced, as a rule, by all specialists of dentistry.

The aim of our work is to determine the indications and contraindications for the treatment of edentulous maxillary lateral incisors and to provide clinical guidelines for the treatment of this disease with the use of dental implants.

Materials and methods for the clinical study. The present study was based on the clinical results of treatment of patients with edentulous maxilla lateral incisors, applied at the North Caucasian Medical Center from 2012 to 2020.

The total number of patients referred for treatment was 16. It should be noted that all of the patients were women age 18 to 32 years (Fig. 1). All patients had bilateral adentia of the lateral incisors; 9 of the 16 patients had previous orthodontic treatment for a period of one to seven years before coming to our clinic. This small number of patients makes it difficult to develop meaningful statistical data processing using mathematical analysis.

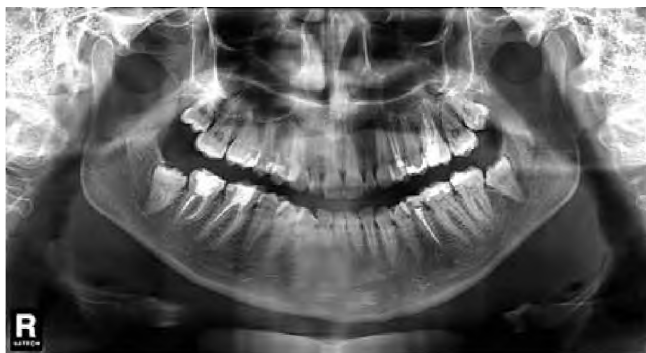

Fig.1. Patient D. 32 years, absent teeth 1.2 and 2.2.

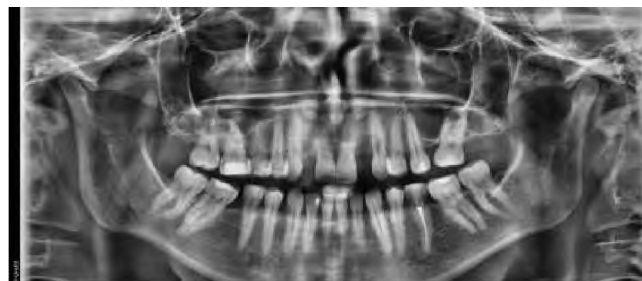

Fig. №2. Panoramic X-ray patient at the time of treatment.

To prepare for the operation, a clinical and laboratory examination of patients was carried out. The X-ray examination of the teeth and jaws was conducted (digital intraoral X-ray images, pantograms, CT-scans with three-dimensional reconstruction of the image).

The possibility of implant placement was decided based on modeling the situation dictated by conditions in the mouth, the condition of the bone bed, as well as the topography of the roots of adjacent teeth. For this purpose, the models determined by the magnitude of the defect and the topography of the alveolar ridge, the distance between the contact surfaces of the interproximal canines and central incisors, the degree of atrophy of the alveolar bone, the type of occlusion, the occlusal surface shape, etc.

In a study of using radiographic techniques (dental radiography, panoramic radiography, compute tomography) evaluated the following parameters:

- the condition of the jaw bones and bone density in the area of implantation, the nature of trabecular pattern and the presence of the closing plate;
- the position of the rudiments of permanent teeth (if they exist);
- the position of the roots of teeth in relation to each other;
- the condition of the boundary between the departments of the alveolar bone around the teeth is preserved;
- the shape of the elements of the temporomandibular joint.

In the preoperative period, it is necessary to conduct thorough sanitation of the oral cavity and orthopedic preparation. The future position of the implant and abutment was planned by a team of dental specialists (dentist orthopedic and dental technician), who carried out the operation of dental prosthesis after implantation. We evaluated the overall level of risk.

At the examination stage, we made up a treatment plan that includes orthodontic treatment (when we did not have enough space for an implant), implant surgery and orthopedic treatment.

Insufficient distance was found between interproximal surfaces of canines and central incisors.

After the studies and diagnosis were made, a treatment plan was drawn up, including orthodontic treatment (with the initial absence of a place for the installation of implants), implantation followed by prosthodontic treatment. In five patients at the examination stage, insufficient distance (from 3 to 5 mm) was found between interproximal surfaces of canines and central incisors.

In clinical situations where the distance was less than 4 mm, we considered the orthodontic closure of the defect by displacement of canines. When this distance was about 4 to 5 mm distal displacement of canines, we proposed creating space for installation of dental implants.

A complex clinical situation is the absence of lateral incisors of the upper jaw, in which the distance between the interproximal surfaces of the canines and central incisors are in the 5-6 mm range.

As an example, we cite the following case report.

In the North Caucasian Medical Training center, the patient I., age 24, visited us with complaints of the loss of teeth in the anterior maxilla. This patient has missing lateral incisors of the upper jaw since his childhood. At the age of 17, she received a removable prosthesis.

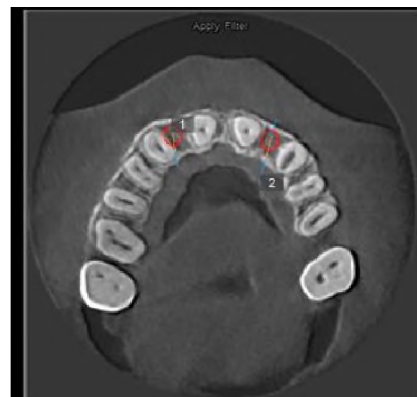


Fig. 3. Scan of the patient.

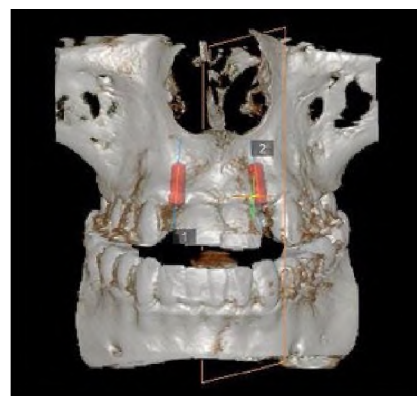


Fig. 4. Scan of the patient digital images showing the planned position of the implants.

At the time of treatment, the patient didn't have 1.2 and 2.2 teeth in positions, and she had a lack of the bone crest in the horizontal alveolar ridge. (Fig. 2).

The distance between the roots and the interproximal surfaces of the central incisors and canines determined according intraoral radiographs as 5-6 mm. The implants installation was planned with implant templates that were imaged with digital software (Fig. 3, 4).

We regarded the overall risk as high according to the SAC system (according to the recommendations of ITI, 2009).

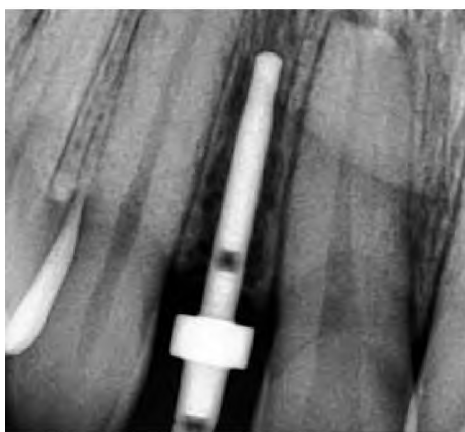

Fig. 5. Intraoperative dental X-rays made to check the parallel positioning of the implants. In the areas of 1.2 and 2.2 teeth, two implants of 3.6 diameter and 10 mm length were installed.

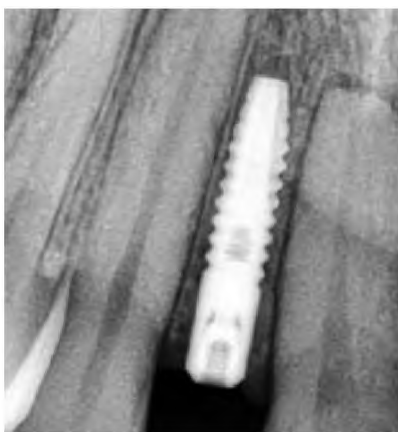

Fig. 6a, b. X-ray control for 3 months after surgery.

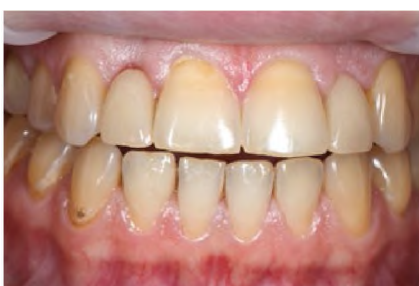
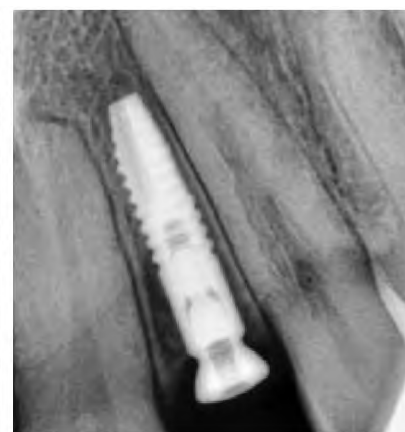
Fig. 7. Type of temporary crowns on implants 2.1. and 2.2.

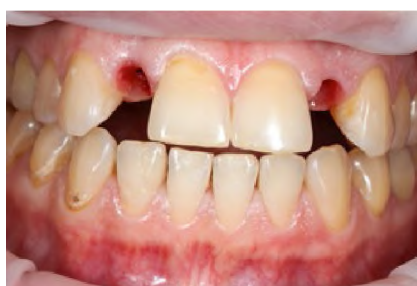

Fig. 8. View of newly formed scalloped edge of the gums in zones 1.2 and 2.2.

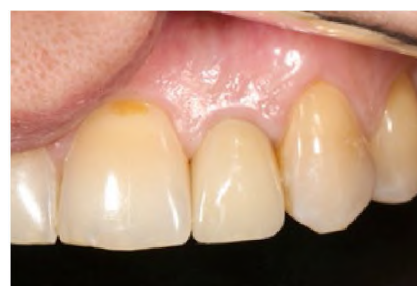

Fig. 9. View of the finished work in the mouth.

It resulted in the following treatment plan:

Installation of implants in the area of teeth 12 and 22 with the delayed function, with simultaneous alveolar ridge augmentation bone replacement material. Further temporary adhesive restorations were made and fixed.

Opening of implants was carried out after 4 month and temporary acrylic crowns were fixed on temporary abutments in 1.2 and 2.2.

The gingival contour was formed with temporary crowns in zone 1.2 and 2.2.

Fixing the permanent crown onto the implant in the area of 1.2 and 2.2.

The operation was begun with a visual assessment of the bone defect.

The measurements taken during the operation showed the width of the alveolar ridge in the area of the missing teeth was 5.5 mm in both zones. The operation was conducted with delayed implant loading according to standard implant procedure. During the operation, Intra-operative dental X-rays to check for parallel positioning of the implants. (Fig. 5).

The bone chips were used for the guided bone regeneration of the alveolar bone after the implant installation. This mixture with bone collagen membrane was closed and sutures were applied. In the postoperative period, there was moderate soft tissue swelling. Analgesics were used no more than 2 days and the patient felt satisfactory.

Three months after implantation, the clinical and radiological signs of osseointegration in the implantation zone appeared (Fig. 6 a,b).

Five months after surgery, the implants were opened and the provisional crowns on temporary abutments were made to create a gingival contour.

The formation of the gum with the help of dental crowns was carried out for 5 months, by the method of correction every 4 weeks of the gingival part of the dental crown (Fig. 7,8).

The creation of the gingival contour with temporary crowns was conducted over 5 months. These temporary crowns were altered with acrylic ones every 4 weeks.

6 months later the implants were opened the temporary crowns were replaced with permanent ones with cement fixation. As supports, individual abutments were made using CAD/CAM technology.

After 6 months, the temporary crowns were removed and new permanent crowns were fixed with cement (Fig. 9).

X-ray examination data at the end of prosthetics showed good signs of osseointegration and high precision of all structural elements (Fig. 10).

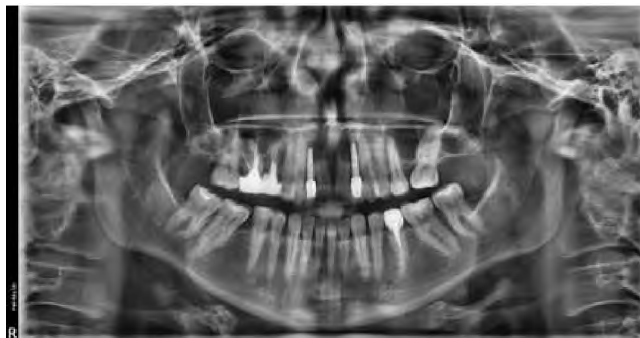

Fig. 10. The final X-ray.

Conclusions and recommendations:

1. Implant treatment of this pathology is recommended only after 18 years, when the maturation of the facial skeleton is ended.
2. If orthodontic treatment is performed at a younger age, this patient's group needs to use removable prosthetic appliances until the facial skeleton is completely formed. Such prosthesis should be adjusted every six months.
3. When the orthodontic treatment is carrying out to expand the space between the central incisors and canines, the implantological treatment should begin not earlier than 6 months after the orthodontic treatment will end.
4. Treatment of patients with adentia of the lateral maxillary incisors requires careful adherence to clinical protocols at all stages of treatment.
5. The minimum allowable distance between the central incisors and canines is 5.5 mm. When the space between the central incisors and canines is expended enough with orthodontic treatment, implant treatment should not be started earlier than 6 months after orthodontic treatment was finished.
6. The formation of the gingival contour using temporary crowns must be part of a clinical protocol of orthopedic procedure for patients with edentulous maxilla lateral incisors.
7. When prosthetics on implants in these clinical situations, preference should be given to CAD/CAM technologies.
8. An interdisciplinary approach must be applied for planning and treatment of patients with edentulous maxilla lateral incisors. Installation of single implants in such case is a predictable treatment, while remaining the method of choice for the clinician.

References

1. Dolgalev A.A. Possibilities of 3D technologies in planning implant treatment / et al. A.Yu. Remov, E.M. Boyko // Russian Bulletin of Dental Implantology. - 2013, No. 1, P.23-27.
2. Johal A, Katsaros C, Kuijpers-Jagtman AM; Angle Society of Europe membership. State of the science on controversial topics: missing maxillary lateral incisors—a report of the Angle Society of Europe 2012 meeting. *Prog Orthod*. 2013 Jul;26(14):20. doi: 10.1186/2196-1042-14-20.
3. Collins R. Restoration of congenitally missing maxillary lateral incisors using mini implants. *Tex Dent J*. 2013 Jul; 130 (7):610-6.
4. Park JH, Okadakage S, Sato Y, Akamatsu Y, Tai K; Orthodontic Treatment of a Congenitally Missing Maxillary Lateral Incisor. *Journal Compilation*: 1708-8240.2010.00356.x Vol 22, N5, 2010.
5. Mummidi B1, Rao CH, Prasanna AL, Vijay M, Reddy KV, Raju MA. Esthetic dentistry in patients with bilaterally missing maxillary lateral incisors: a multidisciplinary case report. *J Contemp Dent Pract*. 2013 Mar 1;14(2):348-54.
6. Sabri R1, Aboujaoude N. Agenesis of the maxillary lateral incisors: orthodontic and implant approach. *Orthod Fr*. 2008 Dec;79(4):283-93. doi: 10.1051/orthodfr:2008020. Epub 2008 Dec 9.
7. Bizetto MS1, Tessarollo FR, Jimenez EE, Guariza-Filho O, Camargo ES, Tanaka OM. Implant rehabilitation of canines in case of bilaterally missing maxillary lateral incisors. *Am J Orthod Dentofacial Orthop*. 2013 Jul;144(1):110-8. doi: 10.1016/j.ajodo.2012.06.020.
8. Andrade DC1, Loureiro CA, Araújo VE, Riera R, Atallah AN. Treatment for agenesis of maxillary lateral incisors: a systematic review. *Orthod Craniofac Res*. 2013 Aug;16(3):129-36. doi: 10.1111/ocr.12015.
9. Al-Ani A.H., Antoun J.S., Thomson W.M., Merriman T.R., Farella M. Hypodontia: an update on its etiology, classification, and clinical management. *Biomed. Res. Int*. 2017.
10. Arandi NZ, Mustafa S. Maxillary lateral incisor agenesis: a retrospective cross-sectional study. *Saudi Dent J*. 2018;30:155-60.

Received 03.11.2021

Revised 04.11.2021

Accepted 21.11.2021

INFORMATION ABOUT AUTHORS

Matyuta Maksim Alekseyevich, Postgraduate Student, Department of General Practice and Pediatric Dentistry, Stavropol State Medical University, Ministry of Health of the Russian Federation, Stavropol, Russian Federation, e-mail: magnum26m@yandex.ru, +7-962-400-36-08.

Edisherashvili Ushangi Besikovich, Postgraduate Student, Department of General Practice and Pediatric Dentistry, Stavropol State Medical University, Ministry of Health of the Russian Federation, Stavropol, Russian Federation, e-mail: ushangi.master@mail.ru, +7-921-535-35-85, ORCID ID: <https://orcid.org/0000-0002-1711-1415>

Dolgalev Alexander Alexandrovich, PhD, MD, Head of the Center for Innovation and Technology Transfer, Professor of the Department of General Practice Dentistry and Pediatric Dentistry of Stavropol State Medical University of the Ministry of Health of the Russian Federation, Professor of the Department of Clinical Dentistry with a course of OS and MFS of Pyatigorsk Medical and Pharmaceutical Institute-branch of the Volgograd State Medical University, Stavropol, Russian Federation, e-mail: dolgalev@dolgalev.pro, +7-962-440-48-61, ORCID: <https://orcid.org/0000-0002-6352-6750>

Stomatov Alexander Vladimirovich, candidate of Medical Sciences, Associate Professor of the Department of Dentistry Penza State University Address: 40 Krasnaya str., Penza, 440026 a_stomatov@mail.ru, tel. +79272893514 ORCID ID: <https://orcid.org/0000-0001-6388-9028>

Lezhava Nino Leonidovna, assistant of the department, Oral and Maxillofacial surgery department, The Peoples' Friendship University of Russia, 6 Miklukho-Maklaya St., Moscow, 117198, Russian Federation; E-mail: +79037244566, pincho72@yandex.ru, ORCID: 0000-0003-0624-843 (https://orcid.org/0000-0003-0624-843X)